

Case Report WI

Treatment of arch length deficiency in an adult male: the extraction of compromised molars rather than healthy premolars

Jon Årtun, DDS, Dr Odont; A. Davide Mirabella, DDS, MSD

The patient presented as a healthy 35-year-old male with a history of no significant medical problems. His oral hygiene was fair and he had several heavily restored molars. The mandibular right second molar was severely decayed and he had not received regular dental treatment. His chief concern was for the irregularity of his anterior teeth.

Diagnostic summary

Extraoral evaluation revealed a well-balanced face with a straight profile and a slightly prominent nose. The lips were retrusive relative to Ricketts' E-line, but nicely curved and well-related to each other (Figure 1).

Model analysis showed a tendency toward Class III molar and Class II canine relationships on the right side with Class I relationships on the left side. Overjet and overbite were normal. A severe arch length deficiency was observed, with a blocked out mandibular right first premolar as well as maxillary and mandibular left canines (Figure 2A-E).

Cephalometric evaluation indicated a slightly retrognathic maxilla and a Class III skeletal relationship. Compensatory proclination of the maxillary incisors and retroclination of the mandibular incisors were observed. The vertical relationships were normal (Figure 3).

Radiographic evaluation showed coronal pulpctomy and periapical lesions on both maxillary and mandibular left first molars. A periapical lesion was also observed on the man-

dibular right second molar due to severe caries. The maxillary right third molar was missing and the maxillary left third molar was peg shaped (Figure 4).

The patient was embarrassed about his smile and very motivated for treatment.

Treatment alternatives

Nonextraction

The arches could be aligned and a good occlusion established without extracting any teeth. However, a nonextraction strategy would require excessive expansion, which was contraindicated in this case. The maxillary incisors were already

Figure 1A-B
Pretreatment facial photographs showing a well balanced face.

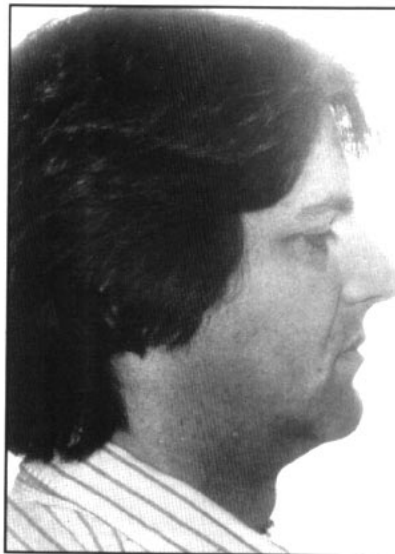

Figure 1A




Figure 1B

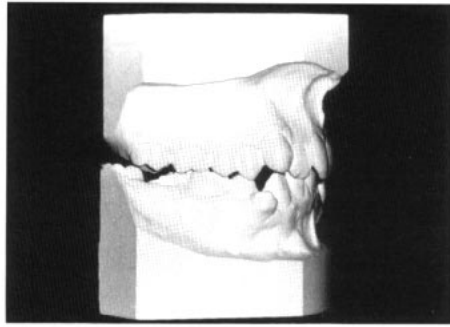


Figure 2A

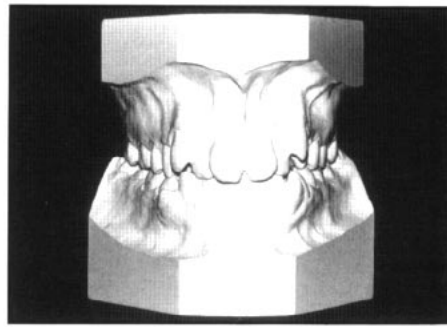


Figure 2B

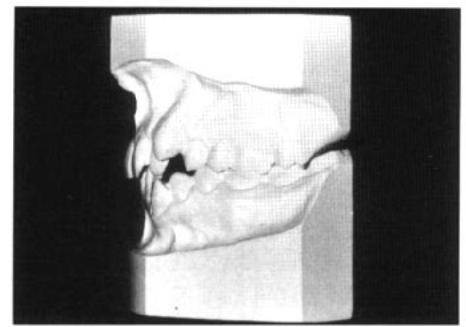


Figure 2C

Figure 2A-E
Pretreatment study models. Note severe arch length deficiency with blocked out mandibular right first premolar as well as maxillary and mandibular left canines.

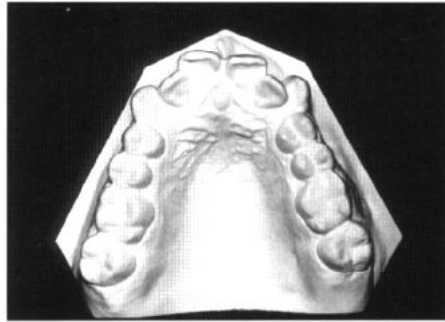


Figure 2D

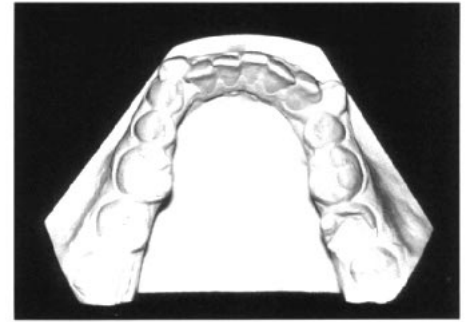


Figure 2E

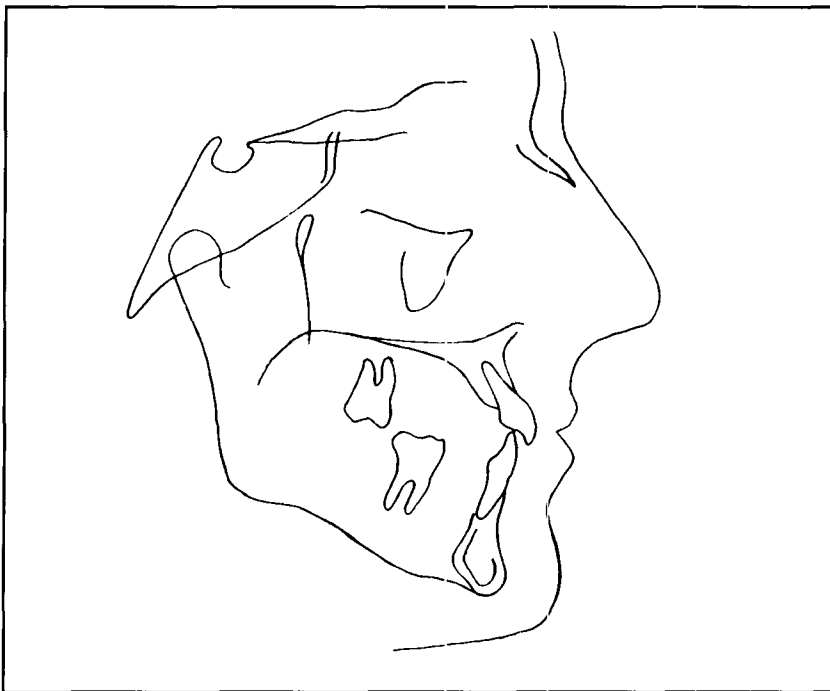


Figure 3

Figure 3
The cephalometric tracing shows a slight Class III skeletal relationship and compensatory incisor inclination. Note the maxillary second and mandibular first molars on right side.

proclined, both clinically and according to cephalometric norms. Proclination of the mandibular incisors might not be associated with a high risk of gingival recession in this case due to a favorable width of the alveolar process in the apical area.¹ However, excessive anterior expansion would probably not be conducive to maintenance of an acceptable overbite. Also, despite the fact that the lips were retrusive relative to the E-line, they were well-balanced and nicely curved and further lip protrusion might not be favorable. Interdental stripping would reduce the need for expansion. In average cases it is possible to strip about 1 mm in each interproximal area without iatrogenic damage.² In this patient, the contact points were located in an area where the enamel was already thin, reducing the potential for stripping.

Lateral expansion is considerably less effective than incisor advancement in increasing arch perimeter.³ Also, the long-term stability of bimaxillary lateral expansion to alleviate crowding has not been sufficiently examined. Inferences from studies on the stability of crossbite correction,^{4,5} follow-up evaluation of cases treated according to Angle's⁶ nonextraction philosophy, and the evaluation of arch form changes during and after treatment⁷ suggest a high risk of relapse.

Extraction

The extraction of four first premolars would facilitate occlusal correction without changing incisor inclination and arch form. However, this

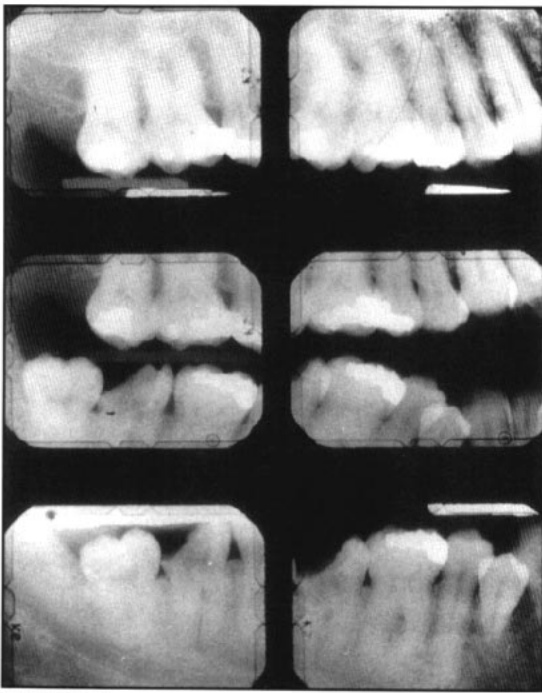


Figure 4A

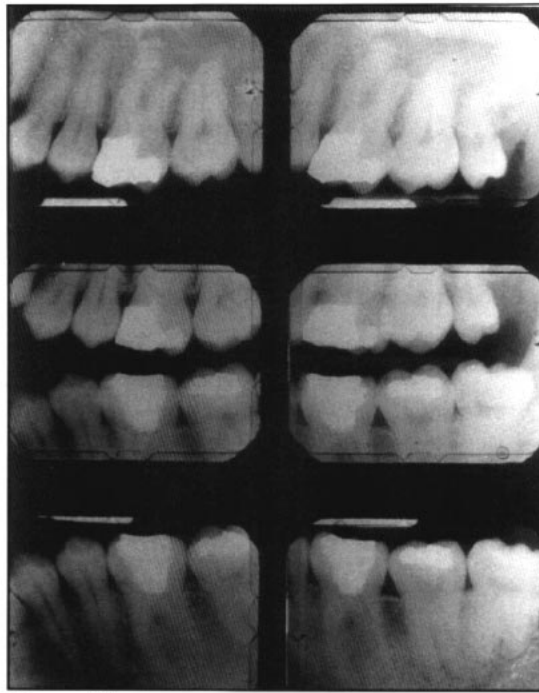


Figure 4B

approach would necessitate extensive restoration of the maxillary and mandibular left first molars and mandibular right second molar. The prognosis of such restorations was questionable. An alternative would involve extraction of the three compromised molars, plus the maxillary right first molar to maintain symmetry. Information on the success of molar extraction in adult treatment is limited. Inferences from studies on orthodontic closure of remodeled, edentulous spaces in the molar areas suggest that incomplete space closure, loss of marginal periodontal attachment, long treatment time, and space reopening represent significant disadvantages.^{8,9,10} Because ridge narrowing had not occurred, incomplete space closure could be avoided with careful mechanics. The risk of periodontal attachment loss would be similar to that seen in premolar extraction cases, and would depend largely on the patient's oral hygiene performance.^{11,12} Space reopening could be prevented through the use of a fixed retention consisting of an 0.0195" spiral wire bonded to the buccal surface of the teeth adjacent to the extraction sites. By extracting the molars, comprehensive restorative treatment could be avoided.

Treatment

The second treatment alternative, requiring the extraction of maxillary first molars as well as the mandibular right second and left first molars, was selected. The patient was informed that appliance therapy might take longer than normal

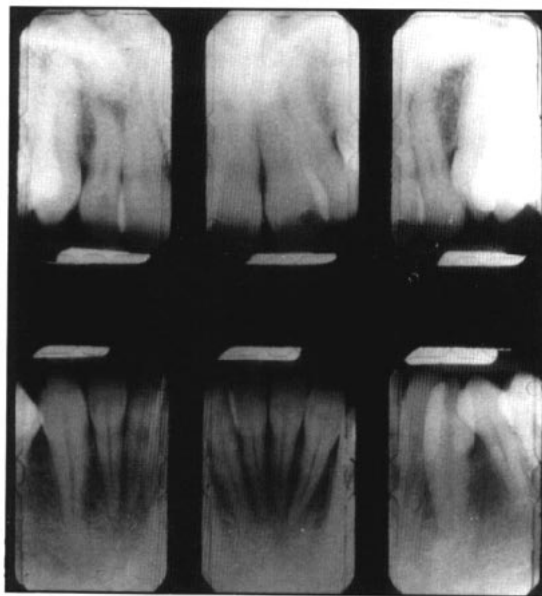


Figure 4C

Figure 4A-C
Pretreatment periapical and bitewing radiographs. Note periapical lesions on maxillary and mandibular left first molars and mandibular right second molar.

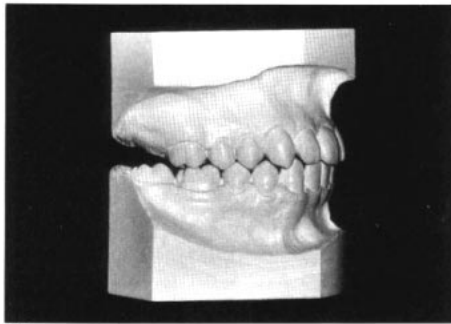


Figure 5A

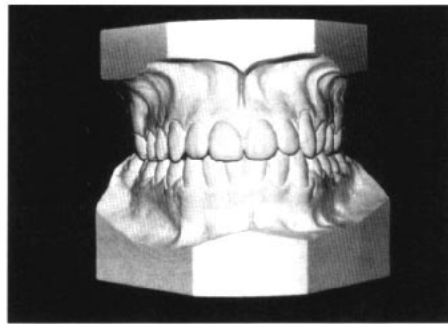


Figure 5B

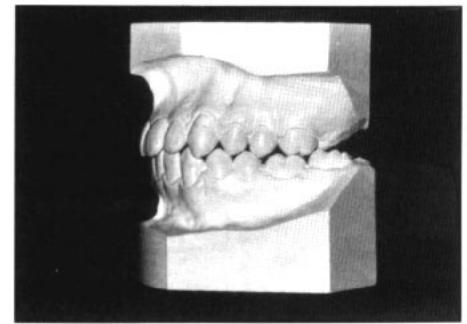


Figure 5C

Figure 5A-E
Posttreatment study models. Note poor occlusal contact between maxillary second and mandibular third molars.

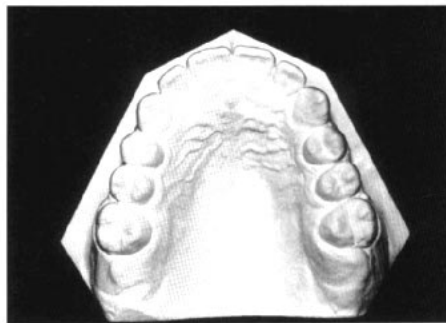


Figure 5D

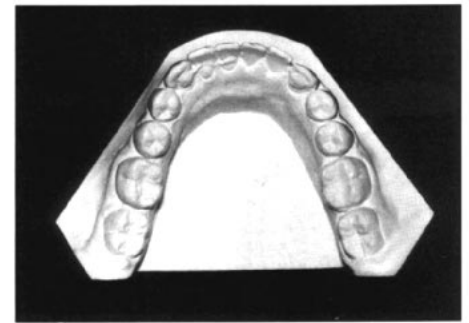


Figure 5E

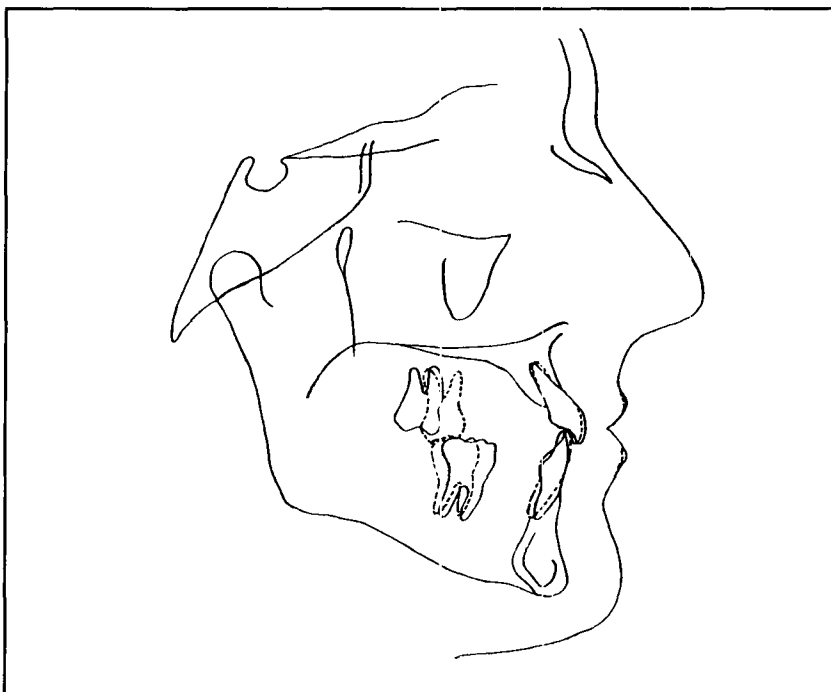


Figure 6

Figure 6
Cephalometric superimposition showing minimal change in incisor position and maintenance of favorable lip relationship.

and that a high level of oral hygiene was imperative.

Initially, all molars and premolars, except the mandibular right first premolar, were banded or bonded. After leveling, the maxillary premolars and the mandibular right first molar and second premolar and left premolars were retracted in a friction-free manner using rectangular sectional wires with closing loops in the extraction sites. A transpalatal arch was used to reinforce maxillary anchorage. The remaining teeth were bonded when enough space was created to allow alignment without arch expansion. The remaining spaces were closed using continuous rectangular archwires and Alastic chains. Interarch elastics were used as needed throughout treatment. Patient compliance was excellent and active treatment was completed in 37 months.

Results

A favorable occlusal result was achieved as a result of this approach to treatment. Interdigitation was acceptable, except for the poor occlusal contact between the mandibular third and maxillary second molars (Figure 5A-E). Equilibration of the pointed cusp tips was postponed until occlusal settling had occurred. The teeth were aligned without changing arch form. Spaces were closed through distal movement of premolars and canines and mesial movement of the molars with minimal change in incisor position, thus maintaining the favorable lip relationship (Figure 6). In keeping with previous clinical

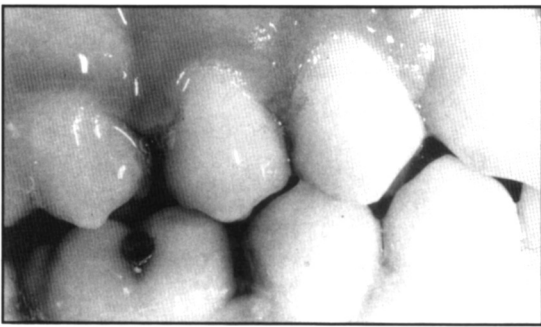


Figure 7A

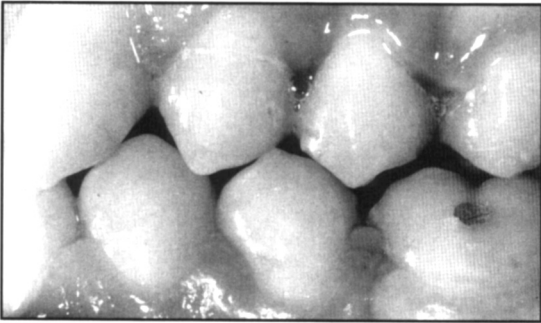


Figure 7B

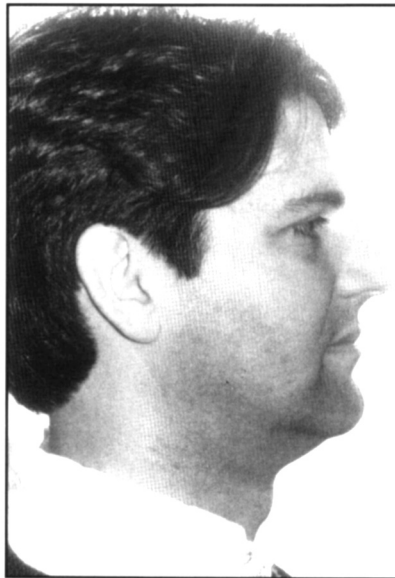


Figure 8A

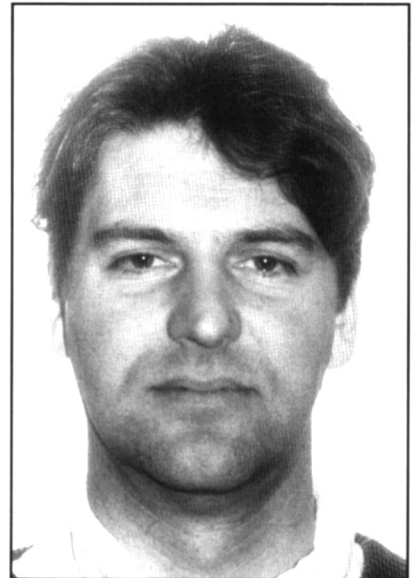


Figure 8B

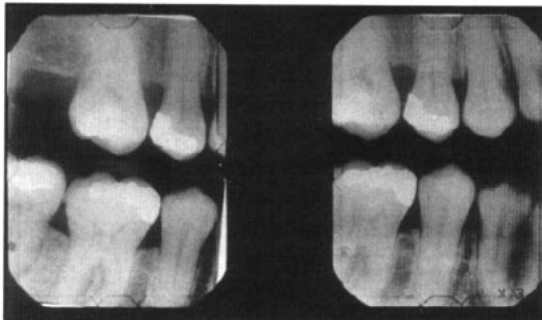


Figure 9A

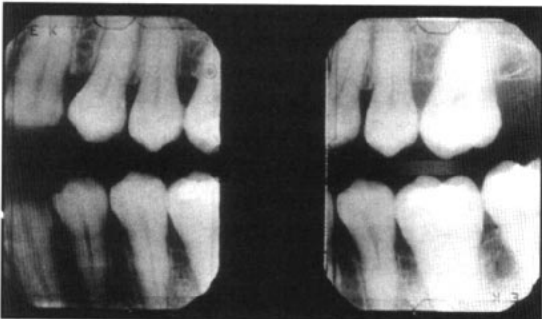


Figure 9C

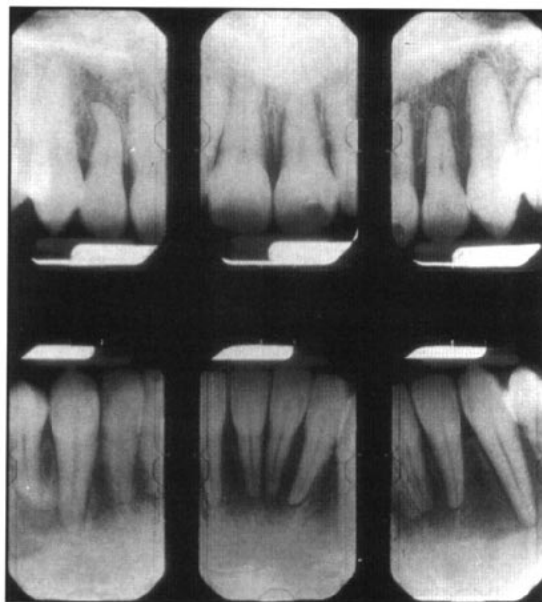


Figure 9B

Figure 7A-B
Posttreatment intraoral photographs. Note gingival clefts in extraction sites.

Figure 8A-B
Posttreatment facial photographs showing well balanced face.

Figure 9A-C
Posttreatment periapical and bitewing radiographs. Note minimal loss of periodontal support in extraction sites.

findings a gingival cleft was present in each extraction site¹³ (Figure 7A-B). However, prior studies suggest that such clefts may remodel over time,^{14,15} reducing the need for surgical removal. Minimal gingival inflammation was seen at the time of appliance removal, despite the use of bands on the molars. Facial balance was maintained (Figure 8A-B) and the alignment of the anterior teeth was improved.

Radiographic evaluation revealed acceptable tooth inclinations and minimal loss of periodontal support in the extraction sites (Figure 9A-C). Some apical root resorption was observed, particularly of the mandibular incisors and the left first molar. Only minimal resorption of the maxillary incisors was seen, including the severely dilacerated right lateral incisor.

Retention

A maxillary wrap-around retainer was placed following appliance removal. The patient was instructed to wear the retainer for 24 hours a day for the first 6 months, at night only for another 18 months, and thereafter as needed. A 0.0195" spiral wire was bonded to the lingual surface of each mandibular incisor, canine and first premolar to maintain incisor alignment. A similar wire was bonded to the buccal surface of each tooth adjacent to an extraction site to prevent space reopening. The patient was informed that the lingual retainer should be maintained for several years, while the buccal retainers could be re-

moved after about 6 months. The risk of space reopening should be minimal at that time, due to the satisfactory root parallelism.

Author Address

Dr. Jon Årtun
School of Dentistry
Department of Orthodontics, SM-46
University of Washington
Seattle, WA 98195

J. Årtun, Associate Professor, Department of Orthodontics, University of Washington, Seattle, Washington.

A. Davide Mirabella is in private practice in Catania, Sicily.

References

1. Årtun J, Krogstad O. Periodontal status of mandibular incisors following excessive proclination: A study in adults with surgically treated mandibular prognathism. *Am J Orthod Dentofac Orthop* 1987;91:225-232.
2. Zachrisson BU, Mjör IA. Remodeling of teeth by grinding. *Am J Orthod* 1975;68:545-553.
3. Germane N, Lindauer SJ, Rubenstein LK, Revere LH Jr, Isaacson RJ. Increase in arch perimeter due to orthodontic expansion. *Am J Orthod Dentofac Orthop* 1991;100:421-427.
4. Krebs A. Midpalatal suture expansion studied by the implant method over a seven-year period. *Trans Eur Orthod Soc* 1964;131-142.
5. Cotton LA. Slow maxillary expansion: Skeletal versus dental response to low magnitude force in *Macaca mulatta*. *Am J Orthod* 1988;73:1-22.
6. Tweed CE. Indications for the extraction of teeth in orthodontic procedures. *Am J Orthod Oral Surg* 1944;30:405-428.
7. de la Cruz A, Sampson A, Little RM, Årtun J, Shapiro, PA. Long-term changes in arch form following orthodontic treatment and retention. *Am J Orthod Dentofac Orthop* (in press).
8. Stepovich ML. A clinical study on closing edentulous spaces in the mandible. *Angle Orthod* 1979;49:227-233.
9. Hom BM, Turley PK. The effects of space closure of the mandibular first molar area in adults. *Am J Orthod* 1984;85:457-469.
10. Goldberg D, Turley PK. Orthodontic space closure of the edentulous maxillary first molar area in adults. *Int J Adult Orthod Orthognat Surg* 1989;4:255-266.
11. Ericsson I, Thilander B. Orthodontic forces and recurrence of periodontal disease. An experimental study in the dog. *Am J Orthod* 1978;74:41-50.
12. Hamp S-E, Lundström F, Nyman S. Periodontal condition in adolescents subjected to multiband orthodontic treatment with controlled oral hygiene. *Eur J Orthod* 1982;4:77-86.
13. Edwards JG. The prevention of relapse in extraction sites. *Am J Orthod* 1971;60:128-141.
14. Rivera Circuns AL, Tulloch JFC. Gingival invagination in extraction sites of orthodontic patients: The incidence, effects on periodontal health, and orthodontic treatment. *Am J Orthod* 1983;83:469-476.
15. Årtun J, Osterberg SK. Periodontal status of teeth facing extraction sites long-term after orthodontic treatment. *J Period* 1987;58:24-29.